

Mass involving retromolar trigone in a geriatric lady-diagnostic dilemma

A.S. Date, G. Venkateshwar, T. Pereira, N. Borkhade

Department of Oral and Maxillofacial Surgery, D.Y. Patil School of Dentistry, Navi Mumbai, India

Polymorphous low grade adenocarcinoma (PLGA) is rarely encountered in routine clinical practice. Our patient, 78 year old lady presented with complaint of ill-fitting denture owing to soft tissue mass in retro-molar trigone. she had undergone multiple surgeries for thyroid malignancy. Thus, PGLA was a surprise diagnosis in this case. The differential diagnosis and subsequent clinical course are discussed in the following manuscript.

Key words: Polymorphous, Adenocarcinoma, Medullary, Carcinoma

CLINICAL PRESENTATION

A 78 year old Indian lady was referred to our out-patients department by her dental surgeon for evaluation of swelling in right retromolar trigone.

Patient was a complete denture wearer for many years and reported to her dentist for progressive ill-fitting of lower denture. Dentist discovered a swelling in the right retromolar trigone as probable cause of poor denture fit and was subsequently referred to us.

On questioning, she was aware of swelling which was slowly enlarging over approximately one year. It was painless, was not associated with any discharge, altered sensation in lip or tongue. It posed no difficulty in mastication, swallowing and phonation. So she did not seek early medical advice. There was no history of fever, weight loss, malaise, fatigue and tobacco consumption in any form.

Her medical history revealed that she underwent hemi-thyroidectomy for medullary carcinoma in 1976. This was followed by completion thyroidectomy in 1989 for recurrence and right radical neck dissection in 1998 for nodal recurrence. She was on thyroxin supplement since then. Apart from this, there was no history of major systemic illness.

Clinical examination revealed scar on right side of neck where nodal dissection was carried out in the past. Intra-orally about 3 cm *2 cm *1 cm firm, non-tender, sessile mass was seen occupying lower right retromolar trigone. Overlying mucosa had no obvious ulceration. Lesion was nontender and partially fixed to underlying bone. Rest of the oral cavity was unremarkable and there was no cervical lymphadenopathy (Figs. 1-2). Baseline hemogram was within normal limits.

DIFFERENTIAL DIAGNOSIS

Based on clinical evaluation, we should consider neoplasms and reactive proliferations as diagnostic possibilities. These are as follows in the order of likelihood.

- 1 **Metastatic thyroid carcinoma.** This was considered likely because patient had suffered from this disease in the past. Medullary carcinoma is a tumor of the parafollicular (C cells) derived from the neural crest and not from the cells of the thyroid follicle as are other primary thyroid carcinomas. Involvement of lymph nodes occurs in 50-60 per cent of cases of medullary carcinoma and blood-borne metastases are common. Current recommended treatment

■ Received: August 14, 2018 - Accepted: November 26, 2018

■ Correspondence: Amit S. Date, Department of Oral and Maxillofacial Surgery, D.Y. Patil School of Dentistry, Navi Mumbai 400706, India. E-mail: asdate2001@yahoo.co.in

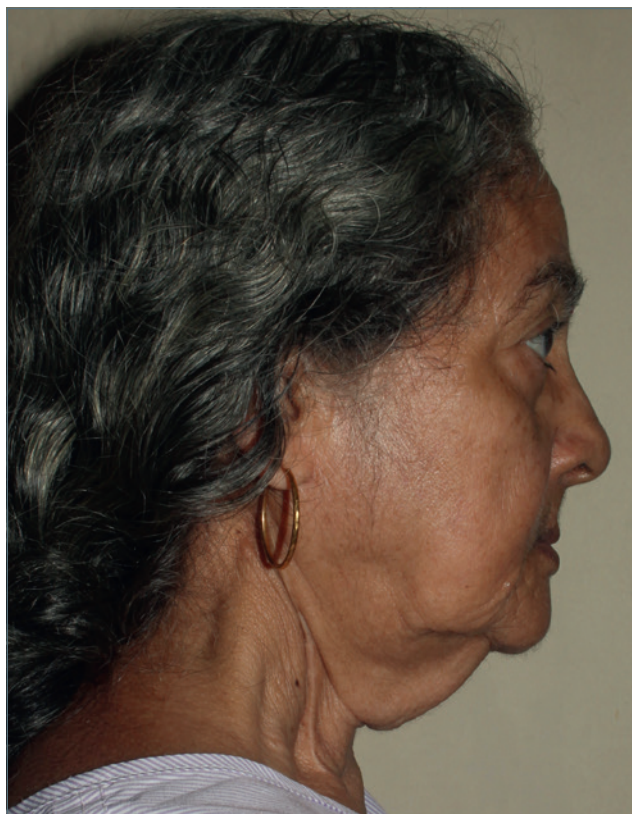

Figure 1. Neck scar.

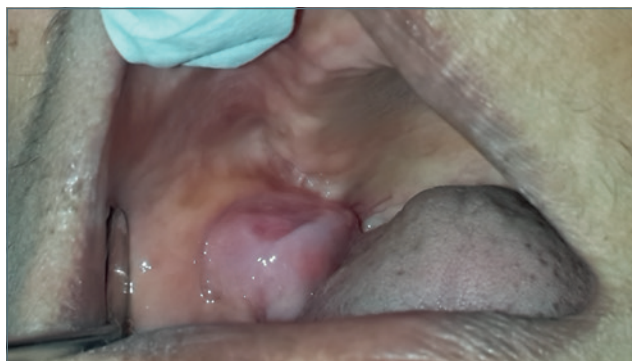

Figure 2. Mass in the right retromolar trigone.

is by total thyroidectomy and either prophylactic or therapeutic dissection of central and bilateral cervical lymph nodes¹. Serum calcitonin which serves to detect recurrence was normal in present case. Thus this diagnosis was ruled out in present case.

- 2 **Minor salivary gland neoplasm.** These account for 10% of all oral cavity malignant neoplasms and 15-23% of all salivary gland malignant neoplasms². This is likely diagnosis due to submucosal location of tumour and advanced age. The precise histotype can only be diagnosed upon biopsy.

Immunohistochemistry (IHC) if needed can be done for pathological diagnosis. Incisional biopsy was done for this patient under local anesthesia.

- 3 **Oral squamous cell carcinoma** is a consideration due to retromolar location and very high incidence of oral cancer in India. However no history of tobacco consumption coupled with submucosal location, non-ulcerated mucosa and absence of cervical lymphadenopathy make this a less likely diagnosis.
- 4 **Reactive lesions** to be considered include pyogenic granuloma, peripheral giant cell granuloma, traumatic fibroma, (due to denture irritation)³. Pyogenic granuloma is more common on labial or buccal gingiva. The surface is frequently ulcerated. Children and pregnant ladies are affected more often. Thus this is unlikely diagnosis. Peripheral giant cell granuloma has a similar clinical appearance but more blue purple compared to bright red color of pyogenic granuloma. It occurs at younger age group (31-41 years) compared to the present case. Traumatic fibroma presents as a pink sessile nodule similar to present case due to some form of chronic irritation. This was a consideration in present case as patient was a denture wearer. However, in radiographs, resorption of the adjacent interseptal bone is commonly seen in both traumatic fibroma and peripheral giant cell granuloma which was absent in present case. Thus, peripheral giant cell granuloma and traumatic fibroma were unlikely diagnoses.
- 5 **Peripheral ossifying fibroma.** It is a non-neoplastic enlargement of the gingival tissue usually from interdental papilla, usually in incisor-cuspid region. It is most common in teenagers and young adults. Thus this is an unlikely diagnosis in present case considering location and age.

DIAGNOSIS AND MANAGEMENT

History and Clinical evaluation was suggestive of neoplastic disorder in the present case. This was confirmed with incisional biopsy and imaging.

Orthopantomogram (OPG) revealed no abnormality apart from soft tissue shadow of the lesion. An incisional biopsy revealed a tumor characterized by nests, acini and cylindroid formation. Cells had pale acidophilic cytoplasm and rounded stippled nuclei. Mitotic activity was not conspicuous. Stroma was focally hyalinized with myxochondroid change. It infiltrated beneath mucosa. Focal neural invasion was noted. To come to definitive diagnosis, IHC was done. Tumor cells expressed ck7, c5/6, vimentin, s-100protein, p63, SMA, calponin, bcl 2, cd117 and galactin3. They were negative for smm, cd10, ck19, ttf1, hbme1 and GFAP. MIB1 proliferation

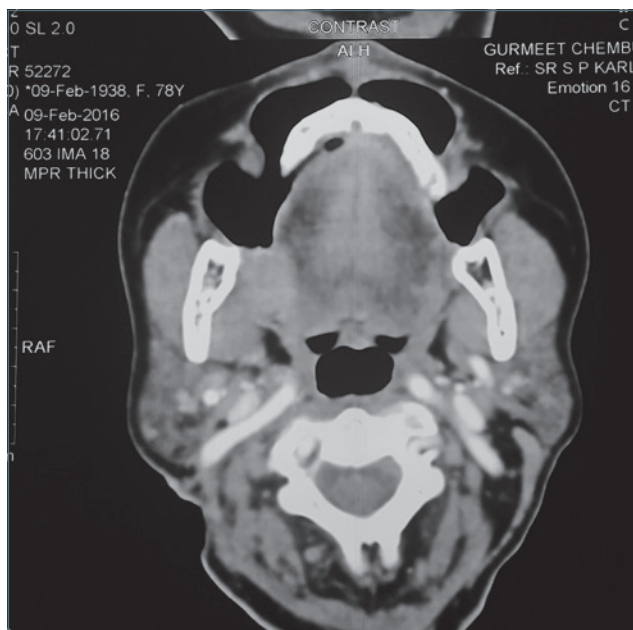

Figure 3. Lesion abutting medial pterygoid.

index was low. Diagnosis of Polymorphous low grade adenocarcinoma (PGLA) was made (Fig. 7), treatment for which is surgical excision.

To access extent and plan surgery CT scan was done which revealed 1.9*1.6*1.8 cm nodular homogenously enhancing lesion in right retromolar trigone. Posteriorly it abutted insertion of medial pterygoid muscle with loss of fat planes (Figs. 3, 4).

Underlying bone, para-pharyngeal space and gingivo-buccal sulci were free. No significant cervical lymphadenopathy was noted.

Owing to her past history of multiple surgeries for thyroid cancer, whole body PET scan was done which revealed similar findings to CT scan and no evidence of distant metastasis (Figs. 5, 6).

TREATMENT

Wide excision of the affected site was done which included lesion, insertion of medial pterygoid muscle (due to involvement on CT scan) and posterior segmental mandibulectomy (clinically tumor fixation to edentulous mandible) (Figs. 8, 9). Subsequently, she underwent external beam radiation to right face (60 Gy/30 fractions) owing to medial pterygoid muscle involvement. (Fig. 10). She is being followed up regularly and free of disease at 2 years (Fig. 11).

The lady did not complain about difficulty in speech and swallowing at the time of follow-up visit. However, due to loss of segment of mandible, she was unable to wear

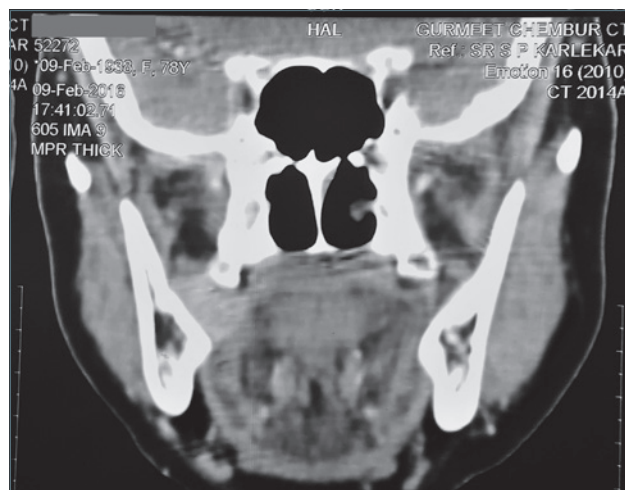


Figure 4. Coronal section of the right retromolar trigone.

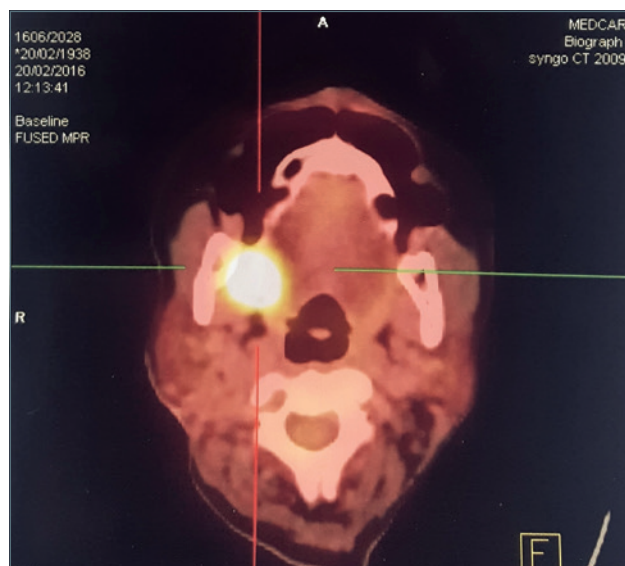


Figure 5. PET scan axial section.

mandibular denture and could only eat soft liquidized food. This was anticipated before operation. It required vascularized bone graft like fibula or ilium to reconstruct lost portion of mandible followed by insertion of titanium dental implants to replace missing teeth. This prolongs operation under general anesthesia to 8-10 hours. In view of her advanced age, this was considered very high anesthetic and surgical risk. The issue was discussed with the patient who opted for removal of tumour and primary closure. Thus her quality of life was affected as far as efficient mastication is concerned.

Histopathology of excisional biopsy specimen confirmed the diagnosis of polymorphous low grade adenocarcinoma (PGLA) made at the time of incisional biopsy (Fig. 12).

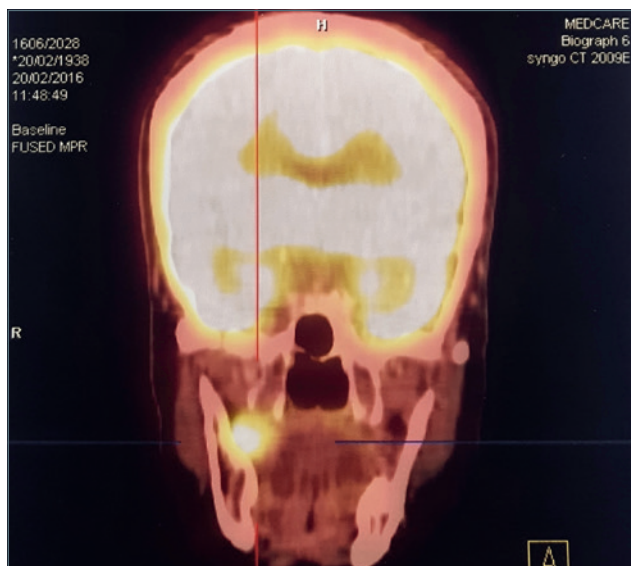


Figure 6. PET scan coronal section.

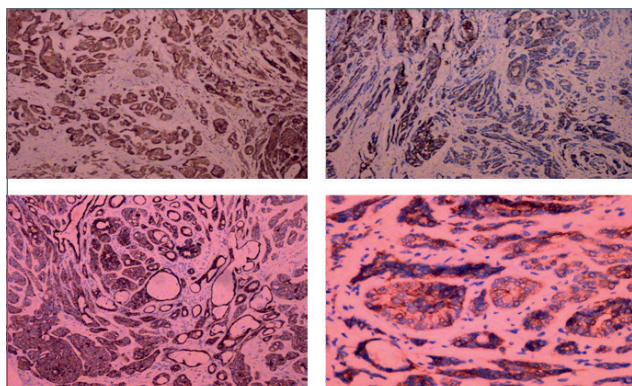


Figure 7. Photomicrograph of the immunohistochemistry (IHC) image of bcl-2 (top left, magnification*10), CD117 (top right, magnification*10), CK7 (bottom left, magnification*10), CD117 (bottom right, magnification*40) in polymorphous low grade adenocarcinoma.

DISCUSSION

Evans and Batsakis in 1984 coined the term PLGA which describes its variable morphological appearances and apparent low-grade behavior⁴. Due to the aggressive clinical behaviour of some of these tumours, the term “low-grade” is omitted but can be used on a case-by case basis⁵. PLGA is a distinct entity due to its architectural diversity, cytological uniformity, and indolent clinical behavior^{6,7}. Its clinical behavior is characterized by slow rate of growth, absence of symptoms, less aggressiveness, minimal metastatic potential and good prognosis⁸. The female-to-male ratio is about 2: 1. More than 70% of patients are

aged 50-70 years. The most common site for PLGA is palate (60% of cases occur in this region) followed by buccal mucosa, upper lip, retromolar triangle and tongue with retromolar area accounting to only 0.5% of tumours^{5-7,9-11}. This case report describes PLGA in such a rare location.

PLGA is typically submucosal in location and unencapsulated.

Neoplastic cells are small to medium-sized and uniform in shape, with bland, minimally hyperchromatic, oval nuclei and only occasional nucleoli. Mitoses are uncommon and necrosis is seen in high-grade transformation. A salient and prominent feature is the wide variation of morphological configurations within and between tumours. The main microscopic architectural patterns are lobular, trabecular, microcystic or cribriform (as in adenoid cystic carcinoma), solid, and papillary-cystic. An eddy-like pattern can be observed at the peripheral boundaries of tumour. Foci of oncocytic, clear, squamous, or mucous cells can be observed.

Tumour stroma can be mucinous or hyalinized.

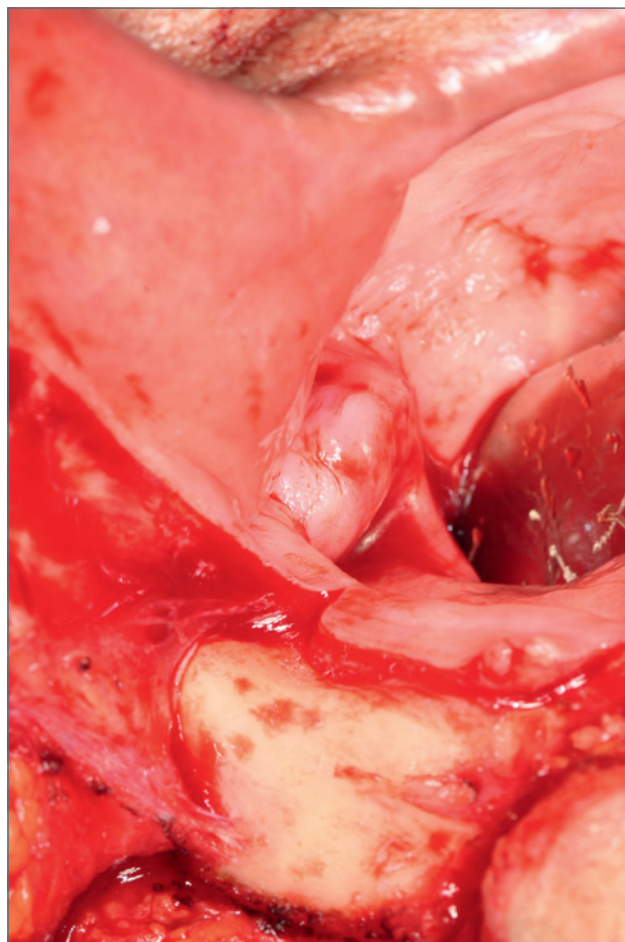


Figure 8. Intra-operative view.

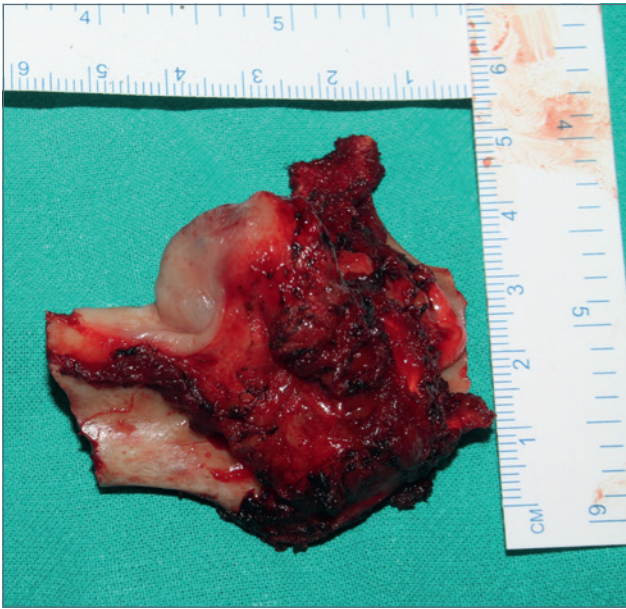

Figure 9. Resected specimen.

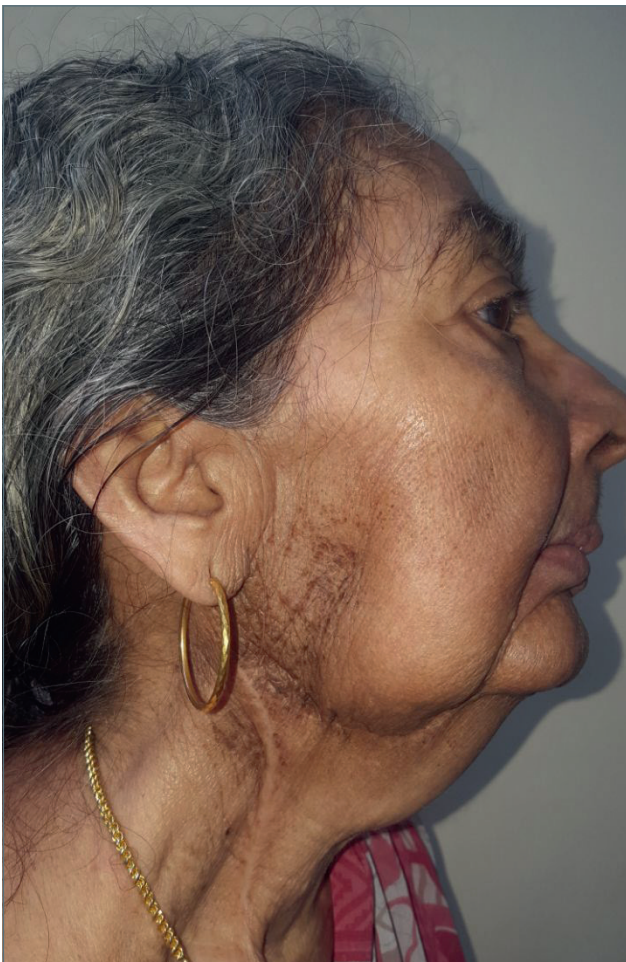

Figure 10. Appearance after radiation therapy.

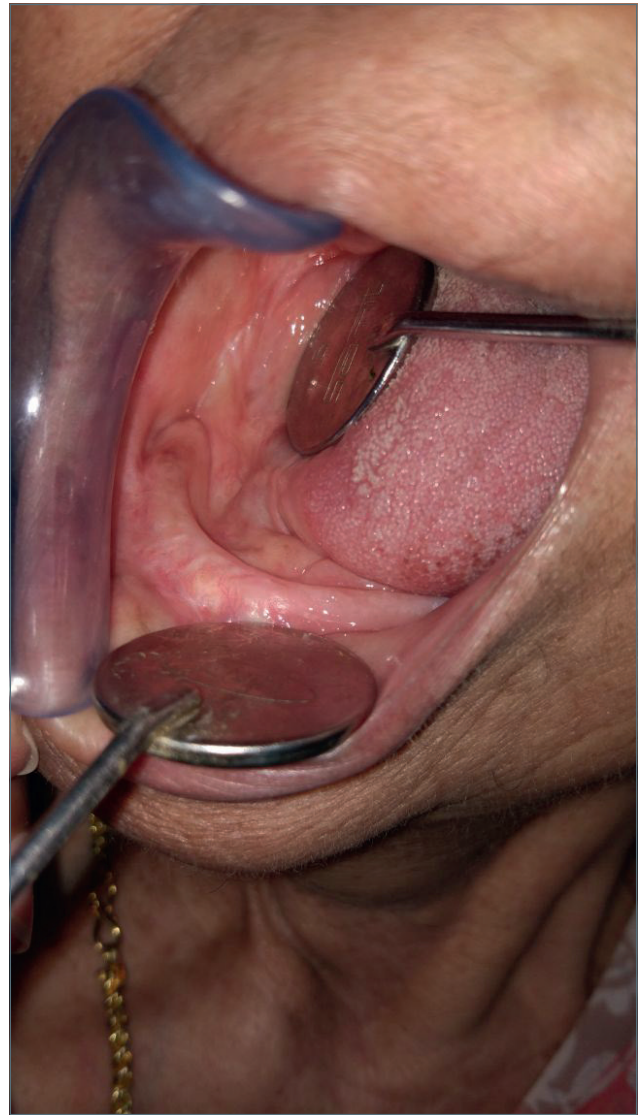

Figure 11. Follow-up picture at 2 years.

Perineural involvement is common. Invasion into adjacent bone may be seen in tumours of the palate or mandible⁵.

Its propensity for occurrence in the palate and indolent clinical features make confusion with pleomorphic adenoma (PA) or adenoid cystic carcinoma (ACC) even more likely. Seen in entirety, the diversity may establish the diagnosis, but in small incisional biopsies, where only a single pattern may be apparent, the lesion can easily be mistaken for a PA, ACC or a basal cell lesion¹². Distinguishing ACC from PLGA of the salivary glands is important for their management. IHC is valuable in unclear PLGA cases. Uniformly positive vimentin and CK7 staining, except for the rare two layer ducts, is sufficient for a final PLGA diagnosis. S100 is also positive

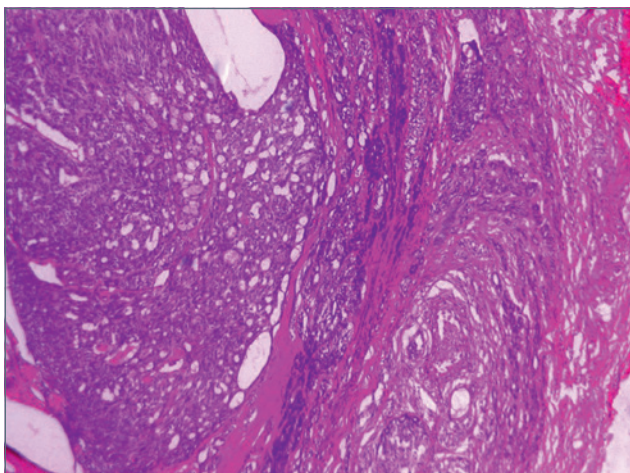


Figure 12. Photomicrograph showing tumour cells arranged in diverse architectural patterns.

in almost all of the cells, but this characteristic is only diagnostically supportive¹³. Wide surgical resection is the mainstay of PLGA treatment and the role of radiation is unclear. Adjuvant radiation therapy is usually given for close and positive margins were present¹⁴. Overall survival is generally good, reported local recurrence rates range from 10-33% (average: 19%). The range of reported regional metastasis rates is 9-15%. Distant metastases have seldom been reported. Deaths have occurred after prolonged periods. High-grade transformation of PLGA has been reported and is associated with an unfavorable prognosis¹⁵. Thus, it is essential to maintain long-term follow up, as local recurrence or metastasis can occur several years later.

CONFLICT OF INTEREST

The authors declare no conflict of interest.

References

- ¹ Williams N, O'Connell PR, McCaskie A, Eds. *Bailey & Love's short practice of surgery*. 26th ed. Boca Raton, FL: CRC Press, pp. 768-9.
- ² González Lagunas J, Rodado C, et al. *Malignant tumors of the minor salivary glands. Retrospective study on 59 cases*. *Med Oral* 2001;6:142-7.
- ³ Seelam S, Beeram RK. *Osteolipoma in the retromolar trigone: a case report and review of literature*. *Ann Maxillofac Surg* 2016;6:304-7.
- ⁴ Evans HL, Batsakis JG. *Polymorphous low-grade adenocarcinoma of minor salivary glands. A study of 14 cases of a distinctive neoplasm*. *Cancer* 1984;53:935-42.
- ⁵ El-naggar AK, Chan JKC, Grandis JR, et al., Eds. *WHO classification of head and neck tumours*. 4th ed. Lyon: IARC Press 2017, p. 167.
- ⁶ Aberle AM, Abrams AM, Bowe R, et al. *Lobular (polymorphous lowgrade) carcinoma of minor salivary glands. A clinicopathologic study of twenty cases*. *Oral Surg Oral Med Oral Pathol* 1985;60:387-95.
- ⁷ Moore BA, Burkey BB, Netteville JL, et al. *Surgical management of minor salivary gland neoplasms of the palate*. *Ochsner J* 2008;8:172-80.
- ⁸ Yih WY, Kratochvil FJ, Stewart JC. *Intraoral minor salivary gland neoplasms: review of 213 cases*. *J Oral Maxillofac Surg* 2005;63:805-10.
- ⁹ Ruiz-Godoy L, Suarez L, Mosqueda A, et al. *Polymorphous low grade adenocarcinoma of the parotid gland. Case report and review of the literature*. *Med Oral Patol Oral Cir Bucal* 2007;12:E30-3.
- ¹⁰ Gupta R, Gupta K, Gupta R. *Polymorphous low grade adenocarcinoma of the tongue: a case report*. *J Med Case Rep* 2009;3:9313.
- ¹¹ Barasoain AM, Martin VFJ, De La Fuente GE, et al. *Polymorphous low-grade adenocarcinoma in the upper lip: a well-described but infrequently recognized tumour*. *Dermat Online J* 2013;19:19265.
- ¹² Speight PM, Barrett AW. *Salivary gland tumours*. *Oral Dis* 2002;8:229-40.
- ¹³ de Araujo VC, Passador-Santos F, Turssi C, et al. *Polymorphous low-grade adenocarcinoma: an analysis of epidemiological studies and hints for pathologists*. *Diagn Pathol* 2013;8:6.
- ¹⁴ Darling MR, Schneider JW, Phillips VM. *Polymorphous low-grade adenocarcinoma and adenoid cystic carcinoma: a review and comparison of immunohistochemical markers*. *Oral Oncol* 2000;38:641-5.
- ¹⁵ Kimple AJ, Austin GK, Shah RN, et al. *Polymorphous low-grade adenocarcinoma: a case series and determination of recurrence*. *Laryngoscope* 2014;124:2714-9.